


CASE REPORT

Open Access



Scleritis following intravitreal brolocizumab injection: a case series

Takuya Takayama¹, Satoru Inoda^{1*} , Hidenori Takahashi¹, Rika Tsukii¹, Hana Yoshida¹, Yuka Kasuya¹, Kosuke Nagaoka¹, Ryota Takahashi¹, Yusuke Arai¹ and Hidetoshi Kawashima¹

Abstract

Background This study reports the first cases of scleritis following intravitreal brolocizumab (IVBr) injection for nAMD, emphasizing the need to be aware of the possibility of scleritis following IVBr injections.

Case presentation Case 1. A 74-year-old Japanese man with nAMD complained of conjunctivitis and decreased vision in the right eye 8 days after his eighth IVBr injection. Examination revealed scleritis without anterior inflammation. Topical 0.1% betamethasone and 0.3% gatifloxacin eye drops were started. The scleritis worsened in the following 2 weeks and became painful. He underwent sub-Tenon's capsule triamcinolone acetonide (STTA) injection. Two days later, he returned with a complaint of severe vision loss. Fundus examination revealed retinal artery occlusion, vasculitis, and vitreous opacity in the right eye. Vitreous surgery was performed. Case 2. An 85-year-old Japanese woman with nAMD in the right eye complained of reddening of the eye 27 days after her fifth IVBr injection. Examination showed conjunctivitis and scleritis without anterior inflammation in the right eye. She was started on 0.1% fluorometholone and 0.5% levofloxacin hydrate eye drops. The scleritis worsened in the following 3 weeks. Her treatment was switched to 0.1% betamethasone eye drops. One month later, the scleritis had improved and a sixth IVBr injection was administered. There was no worsening of the scleritis at that time. However, 1 month after a seventh IVBr injection, she complained of severe hyperemia and decreased vision. Fundus examination revealed vitreous opacification. She underwent STTA, and the vitreous opacity improved in 24 days. Case 3. A 57-year-old Japanese man with nAMD complained of pain and decreased vision in the right eye 21 days after a fourth IVBr injection. Examination revealed scleritis with high intraocular pressure but no anterior chamber or fundus inflammation. STTA and topical eye drops were performed. One month later, scleritis improved but visual acuity didn't due to progression of nAMD.

Conclusions Intraocular inflammation following IVBr injection may progress to the posterior segment. Scleritis can occur after IVBr injection, and topical eye drops alone may not be sufficient for initial treatment. Clinicians should consider the possibility of scleritis in patients with worsening inflammation after IVBr injection.

Keywords Brolocizumab, Scleritis, Intraocular inflammation, Case report

Background

Age-related macular degeneration is a progressive disease and one of the main causes of blindness and decreased vision in the elderly [1]. Brolocizumab is an anti-vascular endothelial growth factor agent that was recently approved as a treatment for neovascular age-related macular degeneration (nAMD). Brolocizumab is expected to have a more prolonged effect than previous treatments and to reduce the treatment burden in patients

*Correspondence:

Satoru Inoda

r1208is@jichi.ac.jp

¹ Department of Ophthalmology, Jichi Medical University, 3311-1 Yakushiji, Shimotsuke-Shi, Tochigi 329-0431, Japan



with nAMD [2]. However, in the Phase III HAWK and HARRIER trials, intraocular inflammation (IOI) was reported to be more common in patients with nAMD who received brodalumab than in those who received aflibercept [3, 4]. Reports of the incidence of IOI following IVBr injection that requires prompt discontinuation and anti-inflammatory therapy range from 2.4 to 19% [4–7]. IOI following IVBr injection includes uveitis, iritis, vitreous opacity, retinal vasculitis, and retinal artery occlusion [8–10]. However, to our knowledge, there have been no reports of scleritis following IVBr injection. We have treated three Japanese patients who developed scleritis following IVBr injection for nAMD.

Case presentation

Case 1

The patient was a 74-year-old Japanese man who had received 11 intravitreal aflibercept injections for pachy-choroid polypoidal choroidal vasculopathy in the right eye over a period of 3 years. His medical history included laparoscopic subtotal esophagectomy for esophageal cancer. There was no history of uveitis or retinal vascular occlusion. Eight days after his eighth IVBr injection, he complained of redness and decreased vision in the right eye (Fig. 1A). Examination revealed scleritis without anterior inflammation in the right eye with a slight increase in intraocular pressure to 24 mmHg but no decrease in visual acuity of 20/25. We diagnosed scleritis, for which he was prescribed 0.1% betamethasone and 0.3% gatifloxacin eye drops four times daily. Two weeks later (26 days after the last IVBr injection), the inflammation had worsened and become painful and intraocular pressure had increased to 27 mmHg. Examination revealed keratic precipitates and fibrin in the vitreous without vasculitis, we diagnosed IOI following IVBr injection. In view of the worsening IOI, he underwent sub-Tenon's capsule triamcinolone acetonide (STTA) injection. Two days later (28 days after his most recent IVBr injection), he complained of severe vision loss. Fundus angiography shows delayed inflow and peripheral arterial occlusion. Fundus examination revealed retinal artery occlusion with vasculitis and vitreous opacity in the right eye (Fig. 1B). Optical coherence tomography of the right eye shows slight hyperreflectivity of the inner nuclear layer (Fig. 1C), and a decrease in visual acuity to 20/500. Vitreous surgery was performed. On examination 39 days later, the patient's scleritis and vitreous opacity had resolved completely and his visual acuity had improved to visual acuity of 20/125 (Fig. 1D).

Case 2

An 85-year-old Japanese woman with type 1 macular neovascularization in the right eye complained of

redness in the affected eye 27 days after her fifth IVBr injection (Fig. 2A). She had hypertension. There was no history of any inflammatory or vascular disease of eye. Visual acuity decreased from 20/20 to 20/25, intraocular pressure was 21 mmHg. The eye showed scleritis without any sign of anterior chamber involvement. She was diagnosed, which was treated with 0.5% levofloxacin hydrate eye drops and 0.1% fluorometholone eye drops three times daily. After 16 days, she complained of hyperemia and heaviness in the eye. Visual acuity was 20/20 and intraocular pressure had increased further to 29 mmHg. Examination revealed slight anterior vitreous cells with scleritis and no anterior chamber inflammation. B-mode ultrasonography did not reveal any signs of posterior scleral thickening. She was started on topical tafluprost combined with timolol maleate eye drops as additional treatment. After 4 days (47 days after her most recent IVBr injection), scleritis did not show any improvement, and the 0.1% fluorometholone eye drops were switched to 0.1% betamethasone eye drops. Seventy days after the most recent IVBr injection, the scleritis improved on the topical therapy (Fig. 2B). Subretinal fluid was seen in the macula at this time. She went on to receive a sixth IVBr injection, after which there was no worsening of her scleritis. Therefore, we did not think that her scleritis was IOI following IVBr at that time. However, a month after a seventh IVBr injection, she complained of worsening scleritis and loss of visual acuity (Fig. 2C). Ophthalmic examination revealed that her visual acuity had decreased to visual acuity of 20/1000 and the intraocular pressure had increased to 24 mmHg. Fundus examination revealed vitreous opacification without hemorrhage but no retinal vasculitis or retinal vascular occlusion (Fig. 2D). At this point, we diagnosed scleritis as IOI following IVBr and performed STTA injection. The vitreous opacity took 24 days to improve (Fig. 2E). By 87 days after STTA, her visual acuity had improved to 20/25 and intraocular pressure was 18 mmHg while on no topical therapy.

Case 3

A 57-year-old Japanese man with type 1 macular neovascularization in the right eye complained of pain and decreased vision in the affected eye 21 days after his fourth IVBr injection (Fig. 3A). His medical history included pancreatitis. His visual acuity decreased from 20/100 to 20/250 and his intraocular pressure was high at 49 mmHg. Examination revealed scleritis but no inflammation in the anterior chamber or fundus (Fig. 3B). Gonioscopy showed no abnormalities like angle nodules, peripheral anterior synechia, or angle neovascularization. He was diagnosed to have IOI following brodalumab injection. He underwent STTA

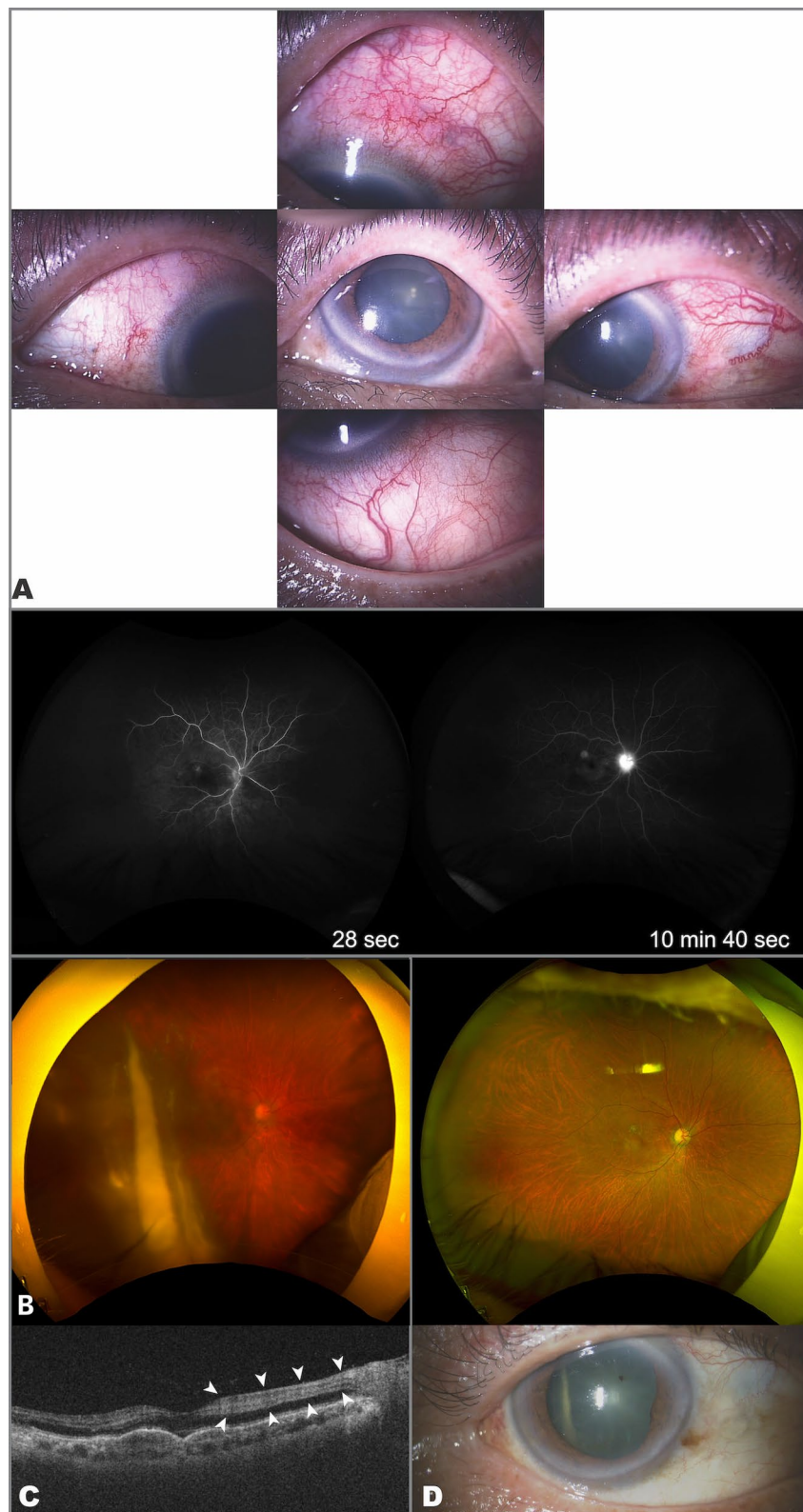


Fig. 1 Clinical findings in Case 1. **A** Significant upper scleritis was observed in the right eye after the eighth intravitreal brolucizumab injection. **B** Fundus angiography shows delayed inflow and peripheral arterial occlusion. Fundus photograph of the right eye shows vitreous opacity and retinal whitening in the upper and temporal macular. **C** Retinal artery occlusion has occurred, and slight hyperreflectivity of the inner nuclear layer is seen in the macula (white arrow). **D** Scleritis and vitreous opacity improved

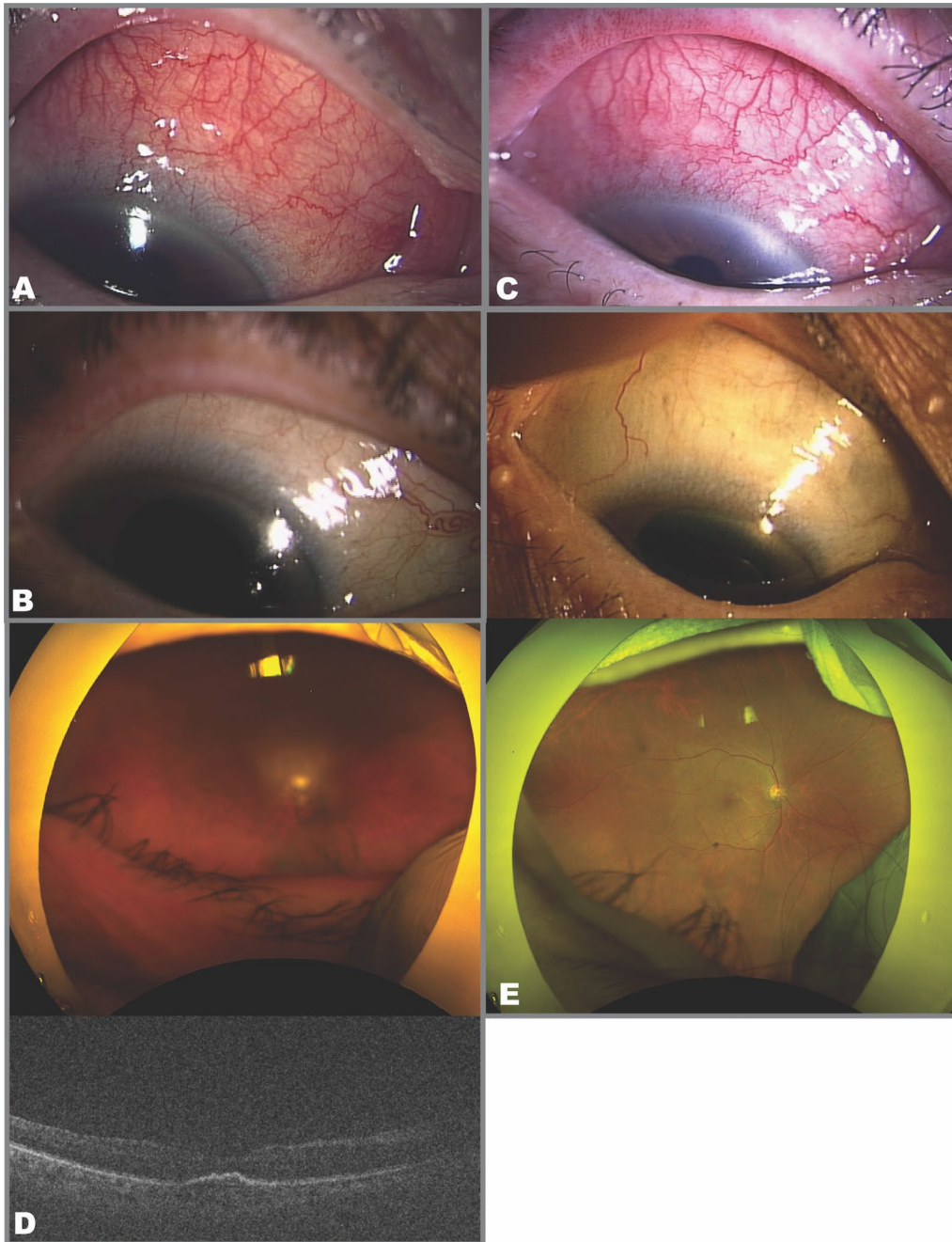


Fig. 2 Clinical findings in Case 2. **A** Significant upper scleritis was observed in the right eye after the fifth intravitreal brolucizumab injection. **B** Scleritis improved after treatment with topical eye drops. **C** Upper scleritis worsened after the seventh intravitreal brolucizumab injection. **D** There was vitreous opacification but no retinal vasculitis or retinal vascular occlusion. The optical coherence tomography image was unclear because of vitreous opacification. **E** Scleritis and vitreous opacity improved

injection and received topical dorzolamide hydrochloride combined with timolol maleate and brimonidine tartrate eye drops. One week later, the scleritis had not resolved and intraocular pressure was still high at 38 mmHg; there was no inflammation or retinal arterial

occlusion on funduscopy (Fig. 3C). The patient was started on 0.1% betamethasone eye drops four times daily, with bimatoprost and ripasudil hydrochloride hydrate. One month later, the scleritis had improved and the intraocular pressure was normal to 14 mmHg,

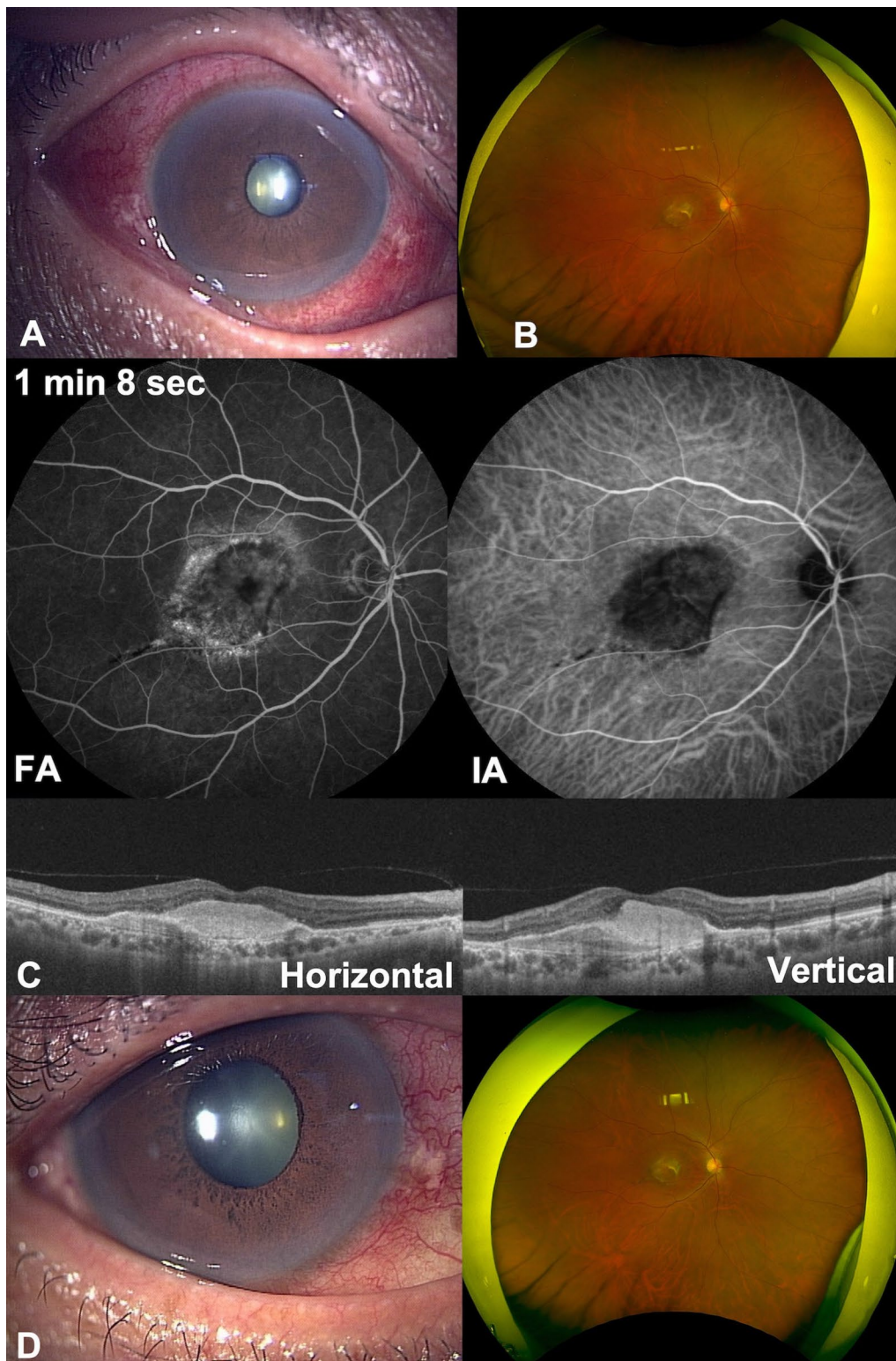


Fig. 3 Clinical findings in Case 3. **A** Scleritis was observed after a fourth intravitreal brotacizumab injection. **B** Fundus images shows no vitreous opacity. **C** Fluorescein angiography and indocyanine green angiography did not show retinal vasculitis or retinal vascular occlusion. Optical coherence tomography showed fibrosis at the fovea centralis. **D** Scleritis gradually improved

although the visual acuity remained at 20/250 because of progression of nAMD (Fig. 3D).

Discussion and conclusions

We have reported three Japanese patients who developed scleritis after IVBr injections for nAMD. In all cases, the affected eyes initially presented without anterior inflammation nor posterior involvement. In the first two cases, we used only topical eye drops as initial treatment. However, after realizing that scleritis can occur following IVBr injection and that inflammation could progress to involve the posterior chamber, we performed STTA and intravitreal triamcinolone acetonide injections, and prescribed oral steroids with topical eye drops as in Case 3.

Although, on all three cases, blood tests and chest radiograph were performed as part of the scleritis investigation, causes like autoimmune disease such as rheumatoid arthritis, anti-neutrophil cytoplasmic antibody associated vasculitis, and systemic lupus erythematosus, infection such as tuberculosis, herpes simplex, varicella zoster virus, cytomegalovirus, human T-cell leukemia virus type 1, toxoplasma, and syphilis [11, 12], no clear cause could be identified. A possible contributing factor to brolocizumab-induced scleritis is the regurgitation of brolocizumab after vitreous injection [13]. One reason to support that the regurgitation is the cause is elevated intraocular pressure. In the extensive Intelligent Research In Sight registry cohort, elevated intraocular pressure was relatively rare, with scleritis being observed in approximately 5% of eyes. Conversely, anterior uveitis was more prevalent, presenting in about 14% of eyes [14]. A prior study identified potential risk factors, such as anterior chamber cells, for ocular hypertension in scleritis patients [15]. In this current series of cases, all the present cases had elevated intraocular pressure and redness with no anterior chamber cells, hypopyon, or fundus inflammation. Thus, the congestion of the pre-canalicular outflow pathway due to debris and cells may not be the primary factor. While the precise etiology of the pressure augmentation remains elusive in these cases, an increased scleral or episcleral vein pressure stemming from an immunological response to brolocizumab might be implicated.

This study has several limitations. In this research, B-mode ultrasonography was performed only for Case 2, and no clear signs of posterior scleral thickening were observed. For Cases 1 and 3, the presence or absence of posterior scleral thickening were unknown. In these three cases, the rise in intraocular pressure occurs without the concurrent presence of anterior chamber inflammation, which distinguishes it from the typical scleritis, which might represent the characteristics of scleritis following IVBr. When IOI occurs following IVBr injection, especially

scleritis, eye drops alone might not be adequate initial treatment.

We have reported three cases of scleritis following IVBr injections. These cases suggest that ophthalmologists should be aware of the possibility of scleritis following IVBr injections. IOI following IVBr injections would get worsen even if the inflammation is only slight or within the anterior chamber. Topical treatment alone might not be adequate initial treatment for IOI following IVBr injections.

Abbreviations

nAMD	Neovascular age-related macular degeneration
IOI	Intraocular inflammation
STTA	Sub-Tenon's capsule triamcinolone acetonide
IVBr	Intravitreal brolocizumab injection

Acknowledgements

Not applicable.

Author contributions

TT: Writing—Original Draft preparation, Visualization, SI: Writing—Review & Editing, Visualization, Project administration, HT: Writing—Review & Editing, Supervision, RT: Resources, Investigation, HY: Resources, Investigation, YK: Resources, Investigation, KN: Resources, Investigation, RT: Resources, Investigation, YA: Writing—Review & Editing, Resources, Investigation, HK: Writing—Review & Editing, Supervision.

Funding

No funding or grant support.

Availability of data and materials

Not applicable.

Declarations

Ethics approval and consent to participate

This study was approved by the institutional review board of Jichi Medical University (JICHI20-127) and adhered to the tenets of the 1964 Declaration of Helsinki and its later amendments or comparable ethical standards. The study procedures followed the guidelines of the institution.

Consent for publication

Written informed consent was obtained from the patients for publication of this case report and any accompanying images. A copy of the written consent is available for review by the Editor-in-Chief of this journal.

Competing interests

The following authors have no financial disclosures: T.T., R.T., H.Y., Y.K., R.T. S.I.: Lecturer's fees from Kowa and Novartis and grants from Novartis, outside this work. H.T.: Patent pending of this work; lecturer's fees from Santen, Kowa, Senju, Novartis, and Bayer; grants from Senju, Novartis, and Bayer; a founder of DeepEyeVision, Inc.; patents outside this work. K.N.: Lecturer's fees from Novartis outside this work. Y.A.: Lecturer's fees from Santen, Kowa, Senju, and Bayer; grants from Heiwa-Iyo, Novartis and Bayer outside this work. H.K.: Lecturer's fees from Otsuka, Senju, Mitsubishi-Tanabe, Kowa, Santen, Novartis, and Zeiss; grants from Senju, Linical, DeepEyeVision, HOYA, Santen, Heiwa-Iyou, and Bayer, outside this work.

Received: 28 August 2023 Accepted: 22 January 2024

Published online: 29 February 2024

References

1. Oshima Y, Ishibashi T, Murata T, Tahara Y, Kiyohara Y, Kubota T. Prevalence of age related maculopathy in a representative Japanese population: the Hisayama study. *Br J Ophthalmol*. 2001;85(10):1153–7.
2. Li E, Donati S, Lindsley KB, Krzystolik MG, Virgili G. Treatment regimens for administration of anti-vascular endothelial growth factor agents for neovascular age-related macular degeneration. *Cochrane Database Syst Rev*. 2020;5(5): CD012208.
3. Patil NS, Dhoot AS, Popovic MM, Kertes PJ, Muni RH. Risk of intraocular inflammation after injection of anti-vascular endothelial growth factor agents: a meta-analysis. *Retina*. 2022;42(11):2134–42.
4. Monés J, Srivastava SK, Jaffe GJ, Tadayoni R, Albini TA, Kaiser PK, *et al*. Risk of inflammation, retinal vasculitis, and retinal occlusion-related events with brodalumab: post hoc review of HAWK and HARRIER. *Ophthalmology*. 2021;128(7):1050–9.
5. Matsumoto H, Hoshino J, Mukai R, Nakamura K, Akiyama H. Short-term outcomes of intravitreal brodalumab for treatment-naïve neovascular age-related macular degeneration with type 1 choroidal neovascularization including polypoidal choroidal vasculopathy. *Sci Rep*. 2021;11(1):6759.
6. Nguyen HV, Tan GS, Tapp RJ, Mital S, Ting DS, Wong HT, *et al*. Cost-effectiveness of a National Telemedicine Diabetic Retinopathy Screening Program in Singapore. *Ophthalmology*. 2016;123(12):2571–80.
7. Montesel A, Bucolo C, Sallo FB, Eandi CM. Short-term efficacy and safety outcomes of brodalumab in the real-life clinical practice. *Front Pharmacol*. 2021;12: 720345.
8. Maruko I, Okada AA, Iida T, Hasegawa T, Izumi T, Kawai M, *et al*. Brodalumab-related intraocular inflammation in Japanese patients with age-related macular degeneration: a short-term multicenter study. *Graefes Arch Clin Exp Ophthalmol*. 2021;259(9):2857–9.
9. Bauman CR, Spaide RF, Vajzovic L, Freund KB, Walter SD, John V, *et al*. Retinal vasculitis and intraocular inflammation after intravitreal injection of brodalumab. *Ophthalmology*. 2020;127(10):1345–59.
10. Bauman CR, Bodaghi B, Singer M, Tanzer DJ, Seres A, Joshi MR, *et al*. Expert opinion on management of intraocular inflammation, retinal vasculitis, and vascular occlusion after brodalumab treatment. *Ophthalmol Retina*. 2021;5(6):519–27.
11. Abdel-Aty A, Gupta A, Del Priore L, Kombo N. Management of noninfectious scleritis. *Ther Adv Ophthalmol*. 2022;14:25158414211070880.
12. Akpek EK, Thorne JE, Qazi FA, Do DV, Jabs DA. Evaluation of patients with scleritis for systemic disease. *Ophthalmology*. 2004;111(3):501–6.
13. Kimura N, Takahashi H, Sakamoto S, Yanagi Y, Maeshima N, Minamimoto A, *et al*. Microvolume analysis of aflibercept in aqueous humor using mass spectrometry. *Transl Vis Sci Technol*. 2022;11(6):7.
14. Armbrust KR, Kopplin LJ. Characteristics and outcomes of patients with scleritis in the IRIS[®] Registry (Intelligent Research in Sight) Database. *Ophthalmol Sci*. 2022;2(3): 100178.
15. Heinz C, Bograd N, Koch J, Heiligenhaus A. Ocular hypertension and glaucoma incidence in patients with scleritis. *Graefes Arch Clin Exp Ophthalmol*. 2013;251(1):139–42.

Publisher's Note

Springer Nature remains neutral with regard to jurisdictional claims in published maps and institutional affiliations.