


CASE REPORT

Open Access



# Fulminant coronavirus disease 2019 meningitis in Iranian infants: a case series

Shahla Afsharpayman<sup>1</sup>, Sedigheh Madani<sup>1,2\*</sup> , Susan Amirsalari<sup>1</sup>, Nooradin Momeni<sup>1</sup>, Mohammad Torkaman<sup>1</sup>, Fatemeh Beiraghdar<sup>1</sup>, Zohreh Kavehmanesh<sup>1</sup> and Zahra Hosseininezhad<sup>1</sup>

## Abstract

**Background** Pediatric coronavirus disease 2019 infection usually presents with respiratory and gastrointestinal symptoms. In this report we present fulminant meningitis as the main presentation of coronavirus disease 2019 without major signs and symptoms of other organs' involvement in 3 infants.

**Cases** The first case was a 4 months Iranian male infant with fulminant meningitis as the main presentation of coronavirus disease 2019 without other organ involvement. He was treated as suspected bacterial meningitis but CSF PCR and CSF culture were negative for common meningeal pathogens. On 3rd day, his coronavirus disease 2019 PCR test became positive, while it was negative on 1st day. The second case was a 13 months Iranian male infant with fever, irritability, and photophobia for 24 h before poorly controlled status epilepticus. CSF coronavirus disease 2019 PCR became positive while CSF PCR and CSF culture were negative for other common meningeal pathogens. Seizures were controlled with multiple anti-seizure medications. The third case was a 14 months Iranian female infant with fever and seizure 1 hour before admission, leading to poorly controlled status epilepticus despite anti-epileptic therapy 10 h after admission. CSF coronavirus disease 2019 PCR became positive while CSF PCR and CSF culture were negative for other common meningeal pathogens. He was controlled with multiple anti-seizure medications.

**Conclusion** Meningitis of coronavirus disease 2019 should be considered in severely ill pediatric cases with poorly controlled seizures and RBC in CSF smear. Also, pediatricians can consider corticosteroids, remdesivir, and IVIG therapy in these cases.

**Keywords** COVID-19, Meningitis, Infant, Children, Case report

## Background

COVID-19 infection in children usually presents with respiratory and gastrointestinal symptoms. Searching PubMed with syntax ("COVID-19"[Mesh] AND "Meningitis"[Mesh]) resulted in 71 articles, out of which, 10 were adults and 4 were pediatric cases reported

with COVID-19 meningo-encephalitis. Also, a systematic review in this regard mentioned 54 cases (mean age  $50.8 \pm 19$  years) reported to have COVID-19 related meningo-encephalitis in which 3 cases had positive CSF PCR for COVID-19. This search result, beside loss of smell and taste sensation following olfactory nerve involvement, demonstrated COVID-19 neurotropic presentation [1–14].

In this report we present fulminant meningitis as the main presentation of COVID-19 without major signs and symptoms of other organs' involvement in 3 infants.

\*Correspondence:

Sedigheh Madani  
[Sedigheh\\_Madani@yahoo.com](mailto:Sedigheh_Madani@yahoo.com)

<sup>1</sup> Department of Pediatrics, Faculty of Medicine, Baqiyatallah University of Medical Sciences, Tehran, I. R. of Iran

<sup>2</sup> Fetal Health Research Center, Hope Generation Foundation, Tehran, I. R. of Iran



© The Author(s) 2024. **Open Access** This article is licensed under a Creative Commons Attribution 4.0 International License, which permits use, sharing, adaptation, distribution and reproduction in any medium or format, as long as you give appropriate credit to the original author(s) and the source, provide a link to the Creative Commons licence, and indicate if changes were made. The images or other third party material in this article are included in the article's Creative Commons licence, unless indicated otherwise in a credit line to the material. If material is not included in the article's Creative Commons licence and your intended use is not permitted by statutory regulation or exceeds the permitted use, you will need to obtain permission directly from the copyright holder. To view a copy of this licence, visit <http://creativecommons.org/licenses/by/4.0/>. The Creative Commons Public Domain Dedication waiver (<http://creativecommons.org/publicdomain/zero/1.0/>) applies to the data made available in this article, unless otherwise stated in a credit line to the data.

### Case 1

An Iranian 4 months well-nourished male infant was referred to the emergency department with fever, poor feeding, and frequent vomiting. His symptoms appeared 12 h before admission and he was severely ill when admitted to PICU. Systemic physical examination showed fever (39 °C), pulse rate 120/min, blood pressure 80/50 mmHg, respiratory rate 34/min, hypotonia, sunken eyes, frequent vomiting despite not feeding recently. No respiratory symptoms were observed. Other physical examinations were normal and fontanelles were not bulged. In the neurological examinations, the infant was restless and the cranial nerves examinations were normal. Muscles' tone and force were normal and his deep tendon reflexes were in the normal range. His head circumference was 41.5 cm.

After parents gave written informed consent for procedures, sepsis laboratory work up was performed immediately (Table 1). Retinal funduscopy revealed no edema. Lumbar puncture was done for Cerebrospinal Fluid (CSF) analysis (Table 1). Abnormal staring, oral automatism, and head colonic movements occurred 2 hours after admission. IV phenytoin (20 mg/kg/stat then 2.5 mg/kg every 12 h) was started to prevent another attack of complex partial seizures.

Important laboratory tests are presented in Table 1. CSF smear analysis was in favor of meningitis. Chest X ray illustrated disseminated fine reticular involvement of interstitial tissue of lungs and also cardiothoracic ratio enhancement. Cardiac consultation and echocardiography revealed normal cardiac function.

The patient was treated with intra venous (IV) cefotaxime (50 mg/kg every 6 h), IV vancomycin (15 mg/kg every 6 h), and 48 h IV dexamethasone (0.15 mg/kg every 6 h). Eight hours after admission he became hypothermic (35.5 °C) and his seizures recurred. IV immune globulin (IVIG) (1 gr/kg once), IV acyclovir (20 mg/kg every 8 h), and IV levetiracetam (30 mg/kg/stat then 15 mg/kg every 12 h) were added. Parents did not permit to take the second CSF sample. Thus, meningitis was treated with full anti-microbial and supportive treatments. Brain MRI revealed frontal sub-arachnoid CSF accumulation (Fig. 1). Serial head circumference measurement was performed and accelerated rate was not detected.

His general condition improved considerably and no fever was recorded after 2 days. However, on 3rd day he had clear coryza and mild diarrhea for one day. Infant's second pharyngeal COVID-19 PCR was positive but CSF COVID-19PCR was not done.

CSF culture and CSF PCR were negative for common bacterial and viral pathogens of meningitis. In accordance to his good general condition and normal laboratory test on 6th day, anti-microbial therapy (cefotaxime, vancomycin, acyclovir) was discontinued. Phenytoin

(2.5 mg/kg every 12 h) and levetiracetam (15 mg/kg every 12 h) were administered orally.

He was seizure free for 3 months after discharge and had normal neurological function and electroencephalogram (EEG). The oral phenytoin was then tapered off, and oral levetiracetam (15 mg/kg every 12 h) was continued. After 6 months of follow up, he was seizure free with normal neurological function and EEG and oral levetiracetam was tapered off.

### Case 2

An Iranian 13 months male infant was admitted in the emergency department with fever (38.5 °C), heart rate 110/min, respiratory rate 31/min, blood pressure 90/55 mmHg, poor feeding, vomiting, and photophobia from 6 h before admission. The infant's growth and development were normal but he had speech delay before recent sickness. No respiratory symptoms were observed. In the neurological examinations, the infant had irritable cries. Redor, Kernig's, and Brudzinski's signs were negative. Cranial nerves examinations were normal and muscles' tone and force were normal. His deep tendon reflexes were in the normal range and the infant's head circumference was 46.5 cm. Other physical examinations were normal.

After parents gave written informed consent for procedures, sepsis laboratory work up was performed immediately (Table 1). Upward gaze and tonic-colonic movements occurred 12 h after admission. Diazepam (0.2 mg/kg/stat) was injected intravenously but the seizures continued. Therefore, IV Phenobarbital (20 mg/kg/stat) was administered but seizures recurred in an hour and prolonged for more than 10 min. To stop seizure, IV phenytoin (20 mg/kg/stat) then IV levetiracetam (30 mg/kg/stat) were loaded. After control of seizures, phenobarbital (2.5 mg/kg every 12 h) and levetiracetam (15 mg/kg every 12 h) were continued intravenously. Patient brain CT scan (Fig. 2) was normal. Inter-ictal EEG was normal. CSF analysis and other important laboratory tests results are shown in Table 1.

CSF analysis was in favor of meningitis. The patient received IV cefotaxime (50 mg/kg every 6 h), IV vancomycin (15 mg/kg every 6 h), and IV dexamethasone (0.15 mg/kg every 6 h). On the next day, patient was very hypotonic and also had poor sucking. He had some cough with normal respiratory rate (25/min) and oxygen saturation (>94%). Chest X ray (Fig. 2) showed right lung middle lobe consolidation. His COVID-19 PCR of pharyngeal and CSF samples became positive; while, CSF culture, and CSF PCR for common pathogens of meningitis and encephalitis were negative. So, IV cefotaxime (50 mg/kg every 6 h) and IV vancomycin (15 mg/kg every 6 h) were continued for aspiration pneumonia and IV acyclovir was

**Table 1** Laboratory documents of 3 cases during admission

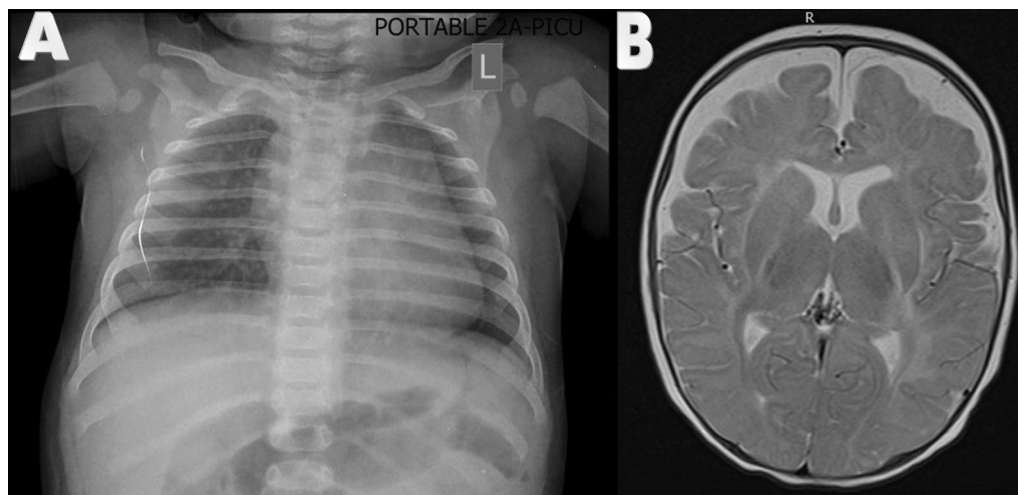
Variables	At admission	During hospitalization	Before discharge
Case 1			
WBC (No.)	12,900	14,800	8400
PMN (%)	71	68	42
Lymphocyte (%)	23	24	57
Platelets (count No.)	325,000	405,000	435,000
ESR (mm/h)	26	105	7
CRP (mg/L)	70	64	5
CSF RBC (No.)	10		
CSF WBC (No.) (PMN%/lymphocyte%)	350 (20/80)		
CSF protein (mg/dL)	172		
CSF glucose (mg/dL)	76		
CSF gram stain	Negative		
CSF culture for bacteria	Negative		
CSF PCR for common bacterial germs of meningitis, HSV, and Candida	Negative		
Pharyngeal PCR for COVID-19	Positive		
CSF PCR for COVID-19	Not performed		
Blood culture (aerobes and anaerobes, and fungus)	Negative		
BUN (mg/dl)	13		
Creatinine (mg/dl)	0.3		
AST (IU/L)	23		
ALT (IU/L)	21		
Urine analysis	Normal		
Urine culture	Negative		
Case 2			
WBC (No.)	18,800	20,500	14,000
PMN (%)	68	81	39
Lymphocyte (%)	23	13	49
Platelets (count No.)	450,000	386,000	402,000
ESR (mm/h)	7	7	5
CRP (mg/L)	3.5	23	5
CSF RBC (No.)	100		
CSF WBC (No.) (PMN%/lymphocyte%)	400 (30/70)		
CSF protein	28		
CSF Glucose	145		
CSF gram stain	Negative		
CSF culture for bacteria	Negative		
CSF PCR for common bacterial germs of meningitis, HSV, and Candida	Negative		
Pharyngeal PCR for COVID-19	Positive		
CSF PCR for COVID-19	Positive		
Blood culture (aerobes and anaerobes, and fungus)	Negative		
BUN (mg/dl)	15		
Creatinine (mg/dl)	0.4		
AST (IU/L)	20		
ALT (IU/L)	23		
Urine analysis	Normal		
Urine culture	Negative		
Case 3			
WBC (No.)	14,300	11,000	4400
PMN (%)	71	65	39

**Table 1** (continued)

Variables	At admission	During hospitalization	Before discharge
Lymphocyte (%)	23	28	55
Platelets (count No.)	82,000	230,000	230,000
ESR (mm/h)	54	41	41
CRP (mg/L)	14	34	9
CSF RBC (No.)	110		
CSF WBC (No.) (PMN%/lymphocyte%)	0		
CSF Protein (mg/dL)	14		
CSF Glucose (mg/dL)	77		
CSF gram stain	Negative		
CSF culture for bacteria	Negative		
CSF PCR for common bacterial germs of meningitis, HSV, and Candida	Negative		
Pharyngeal PCR for COVID-19	Negative		
CSF PCR for COVID-19	Positive		
Blood culture (aerobes and anaerobes, and fungus)	Negative		
BUN (mg/dl)	10		
Creatinine (mg/dl)	0.5		
AST (IU/L)	19		
ALT (IU/L)	21		
Urine analysis	Normal		
Urine culture	Negative		

CSF and blood samples for aerobic, anaerobe, and fungus were collected and transported in sterile condition at admission time. Blood sample was obtained in sterile condition for common viral, bacterial, and fungal pathogens and PCR. CSF samples were obtained and transferred in sterile condition for COVID-19 infection test

WBC white blood cells, PMN Polymorph nuclear neutrophils, ESR Erythrocyte sedimentation rate, BUN Blood urea nitrogen, AST Aspartate aminotransferase, ALT Alanin aminotransferase, PCR polymerase chain reaction, CRP C-reactive protein

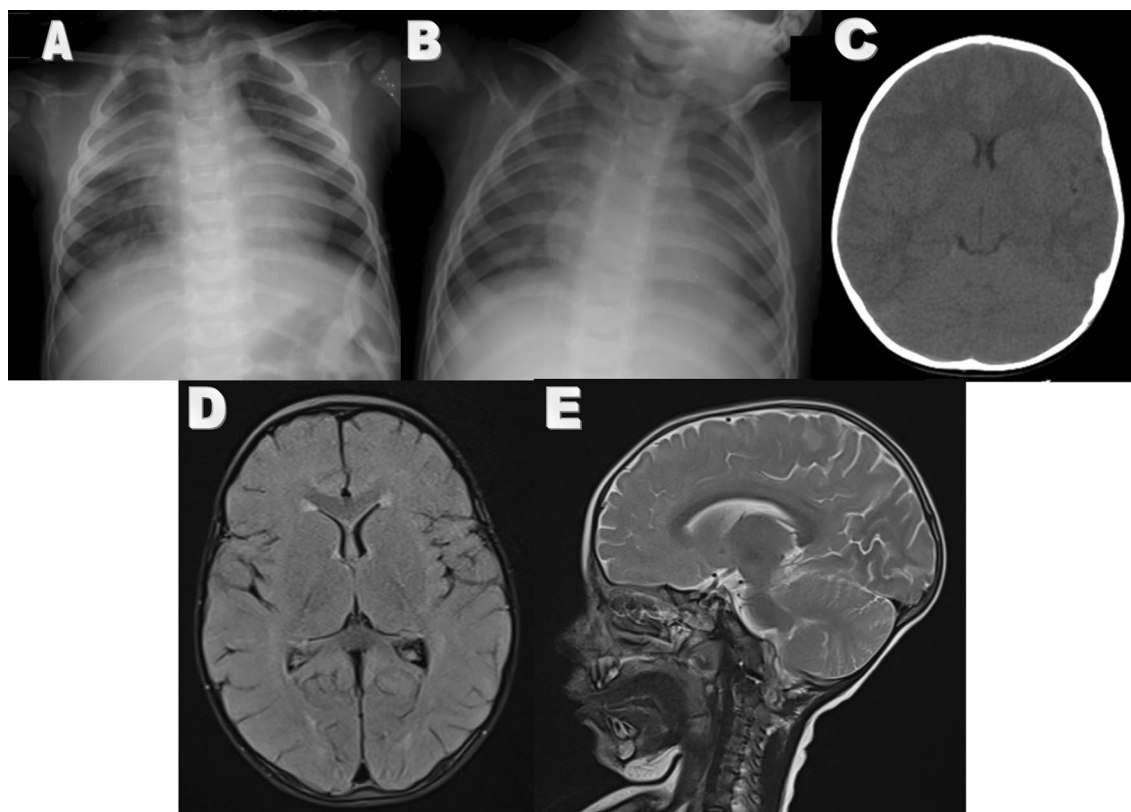


**Fig. 1** **A** Brain MRI of case 1 revealed Sub-Arachnoid fluid accumulation without hydrocephalus. **B** Chest X ray illustrated disseminated fine reticular involvement of interstitial tissue of lungs and cardiothoracic ratio enhancement

discontinued. With considering COVID-19 infection, IV Dexamethasone (0.15 mg/kg every 6 h) was continued for 5 more days and IV remdesivir (first day 5 mg/kg/day and

next 4 days 2.5 mg/kg/day) were added because of prolonged fever.

Cardiac consultation and echocardiography revealed normal cardiac function. Neurologic consultation was



**Fig. 2** First chest X ray (A) illustrated right lung middle lobe consolidation and the second one (B) was normal. Brain CT (C) and Brain MRI (D, E) of case 2

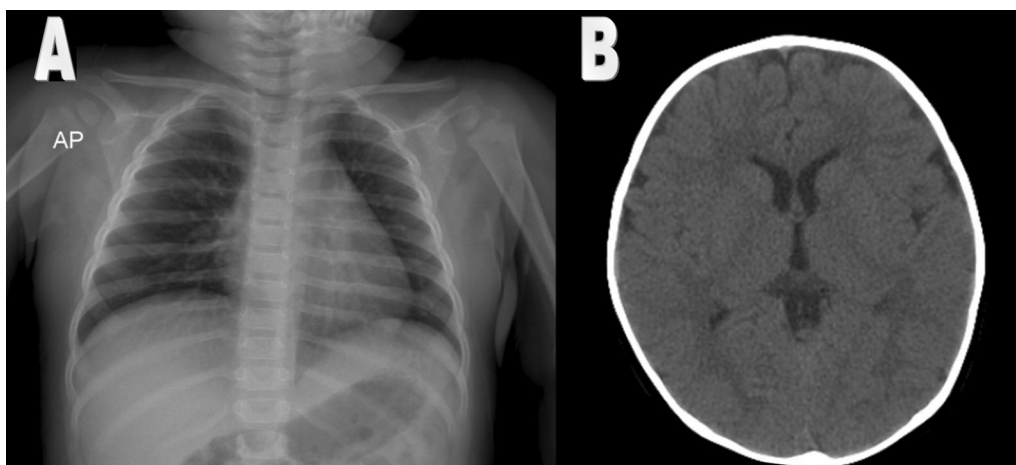
performed for his hypotonia, and neurologist recommended reducing IV phenobarbital (1.5 mg/kg every 12 h). Brain MRI was normal for age (Fig. 2). After 2 days, fever, hypotonia, and photophobia were resolved. A week after admission, some papular rash appeared on the stomach and thigh. Papular rash disappeared after stopping phenobarbital with hydrocortisone and cetirizine therapy. Clobazam (2.5 mg every 12 h) was added instead of phenobarbital. Chest X ray became clear after 12 days (Fig. 2). So, cefotaxime and vancomycin were discontinued after 14 days and infant was discharged with oral clobazam (2.5 mg every 12 h) and oral levetiracetam (15 mg/kg every 12 h). After 3 months, he was seizure free and had normal EEG, so anti seizure medications was discontinued gradually. After 6 months he was still seizure free and he was followed for his speech delay that he had before the meningitis.

### Case 3

A 14 months Iranian female infant with fever (39 °C) and seizure was admitted. She had normal growth and milestones. Her illness began with upper respiratory symptoms 4 days before admission. At emergency room, she received IV diazepam (0.2 mg/kg/stat) and after 5 min,

IV phenytoin (20 mg/kg/stat then 2.5 mg/kg every 12 h) was loaded because of prolonged seizure. Then, patient became stable and her respiratory rate, pulse rate, and blood pressure were 28/min, 107/min, and 94/54 mmHg, respectively. Physical examinations were normal after postictal phase and the infant became alert. Neurological examinations such as Redor, Kernig's, and Brudzinski's signs, and cranial nerve functions were normal. Muscles' tone and force were normal, and her deep tendon reflexes were in the normal range. Her head circumference was 47.5 cm.

After 10 h of her first seizure, she developed another poorly controlled status epilepticus. Her second seizure lasted for 15 min and were finally controlled by one dose of IV diazepam (0.2 mg/kg/stat) and IV levetiracetam (30 mg/kg/stat then 15 mg/kg every 12 h). After parents gave written informed consent, additional procedures were performed. Her brain CT scan (Fig. 3) was normal and lumbar puncture had no WBC (Table 1). CXR revealed reticular involvement (Fig. 3) so IV cefotaxime (50 mg/kg/dose every 8 h) was administered for 7 days. Tests results are shown in Table 1. Pharyngeal COVID-19 PCR was negative while CSF COVID-19 PCR became positive, so, IV dexamethasone (0.15 mg/kg every 6 h)



**Fig. 3** In case 3 chest X ray (A) revealed reticular changes and Brain CT scan (B) was normal

was administered for COVID-19 meningitis. CSF culture and CSF PCR for common pathogens of meningitis and encephalitis were negative. Fever resolved on the third day of admission and her general condition improved. She was discharged with oral levetiracetam (15 mg/kg every 12 h) after 7 days. She had normal EEG and was seizure free after 3 months. Therefore, oral levetiracetam was tapered off. During 6 months follow up, she had normal neurological function and normal EEG, without any episode of seizure.

### Discussion

Briefly, the first case was a 4 months male infant with fulminant meningitis as the main presentation of COVID-19 without other organ involvement. He was treated as suspected bacterial meningitis but CSF PCR and CSF culture were negative and on 3rd day, his pharyngeal COVID-19 PCR test became positive, while it was negative on 1st day. The second case was a 13 months male infant with fever, irritability and photophobia for 24 h before poorly controlled status epilepticus. CSF COVID-19 PCR became positive. Seizures were controlled with multiple anti-seizure medications. The third case was a 14 months female infant with fever and seizure 1 hour before admission, leading to poorly controlled status epilepticus despite anti-epileptic therapy 10 h after admission. CSF COVID-19 PCR became positive. He was controlled with multiple anti-seizure medications. All infants improved without sequelae and their anti-seizure medications were discontinued after 3 or 6 months.

We present 3 infants with COVID-19 meningitis and poorly controlled seizures as their main primary manifestation. Despite severe presentations, their clinical condition improved after 2–4 days. Dexamethasone, besides remdesivir, or IVIG was administered immediately after

seizures to cover fulminant meningitis and it seems they had an important role in improving patients' condition.

COVID-19 infection has variety of clinical manifestations in pediatric cases and it mimics a lot of other viral and bacterial infections' manifestations [15]. In addition, previous studies have mentioned considerable mortality and morbidity rate in Iranian infants infected with COVID-19 [16, 17]. To the best of our knowledge there were 2 reports in which an infant and a neonate had meningitis with positive CSF PCR for COVID-19 [1, 18]. In one of these articles, a 5 months old infant presented with the history of 4 days of COVID-19 general symptoms, then meningitis progressed and its general condition worsened until IVIG administration. In the other article, a neonate with poor feeding and lethargy had been worked up for sepsis and his general condition improved with supportive treatments.

Fulminant presentation is a medical indicator for any sudden and rapid progressive process. Fulminant meningitis was previously defined for some bacterial meningitis with rapid progressive meningeal inflammation that leads to severe illness and increased intracranial pressure. In our cases 1 and 2, symptomatic meningitis presented before COVID-19 general symptoms.

In cases 1 and 2, high percentage of lymphocyte and less PMN besides RBC was observed in CSF smear. This pattern has been seen in herpes meningitis and early phase of common bacterial meningitis. So, vancomycin, cefotaxime, and acyclovir were administered until CSF PCR and culture revealed that the source of meningitis was COVID-19. The third case, CSF smear had no WBC but it had 110 RBC. Therefore, in these 3 cases, the common feature was presence of RBC in CSF smear and two cases had CSF smear appeared like herpes meningitis. Preschool children, especially infants are at risk of several

viral infections besides COVID-19. Laboratory changes of COVID-19 mimic different viral and bacterial patterns. For example in case 1, both ESR and CRP values increased initially and then reduced with clinical improvement, but in case 2, the ESR remained unchanged and normal while a mild elevation was seen in CRP level after 3 days of admission. Relative lymphopenia has been considered as a mark for COVID-19 infection especially in pediatric cases and it had been seen in our cases, too.

Chest CT scan is the diagnostic imaging in adults who are infected by COVID-19, but in children is not recommended routinely because of risk of post X ray tumorigenicity [19]. In these cases, we did not perform chest CT scan because they had not prominent respiratory symptoms. This imaging modality can be considered in COVID-19 infected children who have poorly controlled respiratory symptoms.

Brain imaging such as MRI and CT may have some normal variation during infancy. Differentiation between pathologic changes and normal variations will be diagnosed by follow up brain imaging and neurological examinations. In cases 1 and 2, brain MRI was performed for their severe illness and lethargy besides poorly controlled seizures. Because of closed fontanels, brain CT scan was performed in cases 2 and 3, to rule out space occupying lesion and brain edema that could have caused brain hernia during lumbar puncture.

Pediatricians should consider COVID-19 as a potential infection that could have serious manifestations such as rapidly progressive meningitis and start corticosteroid, remdesivir, and IVIG as potential treatments.

## Conclusion

To the best of our knowledge, there is one report of a neonate with COVID-19 meningitis with positive CSF PCR for COVID-19 and here we add 3 more positive CSF PCR for COVID-19 infants in this article. Meningitis of COVID-19 should be considered in severely ill pediatric cases with poorly controlled seizures and RBC in CSF smear. Also, pediatricians can consider corticosteroids, remdesivir, and IVIG therapy in these cases.

## Acknowledgements

The authors would like to thank the nursing staff of Baqiyatallah Hospital for their wholehearted cooperation.

## Author contributions

SM admitted and managed the patient in pediatric intensive care unit and she drafted the manuscript. ShA carried out the pediatric infectious consultation and revised the manuscript. SA and ZH performed pediatric neurologic consultation and revised the manuscript. NM performed cardiac evaluation and echo-cardiographer and revised the manuscript. MT performed infant lumbar puncture and revised the manuscript. FB and ZK participated in drafting. All authors read and revised the manuscript and all of them approved the final manuscript.

## Funding

This work had no funding.

## Availability of data and materials

The data supporting this study finding can be presented by corresponding author if it is needed.

## Declarations

### Ethics approval and consent to participate

Ethical approval was not applicable. This study had no novel intervention and all treatments were standard treatments of an infant with meningitis. All patients' parents gave written, informed consents to publish these cases and any accompanying images.

### Consent for publication

Written informed consent was obtained from the patient's parents for publication of report and any accompanying images. Copies of the written informed consents are available for review by the Editor-in-Chief of this journal.

### Limitation

Lack of enough CSF sample for investigating COVID-19 as meningitis source.

### Competing interests

The authors declare that they have no known competing financial interests or personal relationships that could have appeared to influence the work reported in this paper.

Received: 7 January 2022 Accepted: 1 February 2024

Published online: 20 March 2024

## References

- Arango Ferreira C, Correa-Roda M. Acute meningoencephalitis as initial presentation of SARS-CoV-2 infection in pediatrics. *Pediatr Infect Dis J*. 2020;39(11):e386–7.
- de Oliveira FAA, Palmeira DCC, Rocha-Filho PAS. Headache and pleocytosis in CSF associated with COVID-19: case report. *Neurol Sci*. 2020;41(11):3021–2.
- Duong L, Xu P, Liu A. Meningoencephalitis without respiratory failure in a young female patient with COVID-19 infection in Downtown Los Angeles, early April 2020. *Brain Behav Immun*. 2020;87:33.
- Huang YH, Jiang D, Huang JT. SARS-CoV-2 detected in cerebrospinal fluid by PCR in a case of COVID-19 encephalitis. *Eur J Neurol*. 2020;87:149.
- Khodamoradi Z, Hosseini SA. COVID-19 meningitis without pulmonary involvement with positive cerebrospinal fluid PCR. *Eur J Neurol*. 2020;27(12):2668–9.
- Pouga L. Encephalitic syndrome and anosmia in COVID-19: Do these clinical presentations really reflect SARS-CoV-2 neurotropism? A theory based on the review of 25 COVID-19 cases. *J Med Virol*. 2021;93(1):550–8.
- Chaumont H, Etienne P, Roze E, Couratier C, Roger PM, Lannuzel A. Acute meningoencephalitis in a patient with COVID-19. *Revue neurologique*. 2020;176(6):519–21.
- Dharsandiya M, Shah K, Patel K, Patel T, Patel A, Patel A. SARS-CoV-2 viral sepsis with meningoencephalitis. *Indian J Med Microbiol*. 2020;38(2):219–21.
- Heller HM, Gonzalez RG, Edlow BL, Ard KL, Gogakos T. Case 40–2020: a 24-year-old man with headache and Covid-19. *N Engl J Med*. 2020;383(26):2572–80.
- Moriguchi T, Harii N, Goto J, Harada D, Sugawara H, Takamino J, et al. A first case of meningitis/encephalitis associated with SARS-Coronavirus-2. *Int J Infect Dis IJID*. 2020;94:55–8.
- Naz S, Hanif M, Haider MA, Ali MJ, Ahmed MU, Saleem S. Meningitis as an initial presentation of COVID-19: a case report. *Front Public Health*. 2020;8:474.
- Pandey M. Acute meningoencephalitis in a child secondary to SARS-CoV-2 virus. *Indian Pediatr*. 2021;58(2):183–4.

13. Pawar GR, Ratageri VH. Meningoencephalitis associated with SARS-CoV-2 infection. *Indian J Pediatr.* 2021;88(5):490.
14. Yousefi K, Poorbarat S, Abasi Z, Rahimi S, Khakshour A. Viral meningitis associated with COVID-19 in a 9-year-old child: a case report. *Pediatr Infect Dis J.* 2021;40(2):e87–98.
15. Siebach MK, Piedimonte G. COVID-19 in childhood: transmission, clinical presentation, complications and risk factors. *Pediatr Pulmonol.* 2021;56(6):1342–56.
16. Madani S, Shahin S, Yoosefi M, Ahmadi N, Ghasemi E, Koolaji S, *et al.* Red flags of poor prognosis in pediatric cases of COVID-19: the first 6610 hospitalized children in Iran. *BMC Pediatr.* 2021;21(1):563.
17. Abdolsalehi MR, Madani S, Mahmoudi S, Navaeian A, Khodabandeh M, Sadeghi RH, *et al.* Association of body mass index with COVID-19 outcome in a pediatric tertiary referral hospital in Iran. *Arch Pediatr.* 2023;30:297–301.
18. Jamali Z, Dehghani F, Hosseininasab A. A case report of late-onset neonatal meningitis caused by SARS-CoV-2. *Arch Pediatr Infect Dis.* 2021;10(Suppl): e113879.
19. World Health Organisation. COVID-19 clinical management, living guidance. WHO; 2021.

### **Publisher's Note**

Springer Nature remains neutral with regard to jurisdictional claims in published maps and institutional affiliations.